

## Lovastatin decreases coenzyme Q levels in humans

(hypercholesterolemia/3-hydroxy-3-methylglutaryl-coenzyme A reductase inhibitors/ubiquinone/drug side effects)

KARL FOLKERS\*<sup>†</sup>, PER LANGSJOEN<sup>‡</sup>, RICHARD WILLIS\*, PHILLIP RICHARDSON\*, LI-JUN XIA\*, CHUN-QU YE\*, AND HIROO TAMAGAWA\*

\*University of Texas at Austin, Austin, TX 78712; and <sup>‡</sup>The Health Center at Tyler, The University of Texas at Tyler, Tyler, TX 75710

Contributed by Karl Folkers, June 20, 1990

**ABSTRACT** Lovastatin is clinically used to treat patients with hypercholesterolemia and successfully lowers cholesterol levels. The mechanism of action of lovastatin is inhibition of 3-hydroxy-3-methylglutaryl-coenzyme A reductase, an enzyme involved in the biosynthesis of cholesterol from acetyl-CoA. Inhibition of this enzyme could also inhibit the intrinsic biosynthesis of coenzyme Q<sub>10</sub> (CoQ<sub>10</sub>), but there have not been definitive data on whether lovastatin reduces levels of CoQ<sub>10</sub> as it does cholesterol. The clinical use of lovastatin is to reduce a risk of cardiac disease, and if lovastatin were to reduce levels of CoQ<sub>10</sub>, this reduction would constitute a new risk of cardiac disease, since it is established that CoQ<sub>10</sub> is indispensable for cardiac function. We have conducted three related protocols to determine whether lovastatin does indeed inhibit the biosynthesis of CoQ<sub>10</sub>. One protocol was done on rats, and is reported in the preceding paper [Willis, R. A., Folkers, K., Tucker, J. L., Ye, C.-Q., Xia, L.-J. & Tamagawa, H. (1990) *Proc. Natl. Acad. Sci. USA* 87, 8928–8930]. The other two protocols are reported here. One involved patients in a hospital, and the other involved a volunteer who permitted extraordinary monitoring of CoQ<sub>10</sub> and cholesterol levels and cardiac function. All data from the three protocols revealed that lovastatin does indeed lower levels of CoQ<sub>10</sub>. The five hospitalized patients, 43–72 years old, revealed increased cardiac disease from lovastatin, which was life-threatening for patients having class IV cardiomyopathy before lovastatin or after taking lovastatin. Oral administration of CoQ<sub>10</sub> increased blood levels of CoQ<sub>10</sub> and was generally accompanied by an improvement in cardiac function. Although a successful drug, lovastatin does have side effects, particularly including liver dysfunction, which presumably can be caused by the lovastatin-induced deficiency of CoQ<sub>10</sub>.

In Western countries, the leading cause of death is heart disease. An elevated serum level of cholesterol, known as hypercholesterolemia, is a major risk factor for heart disease. The Framingham Clinical Study (1) and the British Regional Heart Study (2) supported the interpretation that serum levels of cholesterol correlate with risk. In the human body,  $\geq 50\%$  of cholesterol is formed by intrinsic biosynthesis from acetyl-CoA (Fig. 1).

HMG-CoA is enzymically converted to mevalonate by HMG-CoA reductase, which was therefore considered a prime enzyme for pharmacological intervention. Endo *et al.* (3) characterized a metabolite from *Penicillium citrinum* that was identical to a metabolite characterized by Brown *et al.* (4) from *Penicillium brevicompactum* that reduced cholesterol levels in plasma from monkeys and humans, but not from rats or mice (Alberts *et al.*, ref. 5). This metabolite, ML-236 B, was an extremely potent competitive inhibitor of HMG-CoA reductase. Alberts *et al.* (5) characterized a metabolite from *Aspergillus terreus* that was a more active inhibitor of HMG-

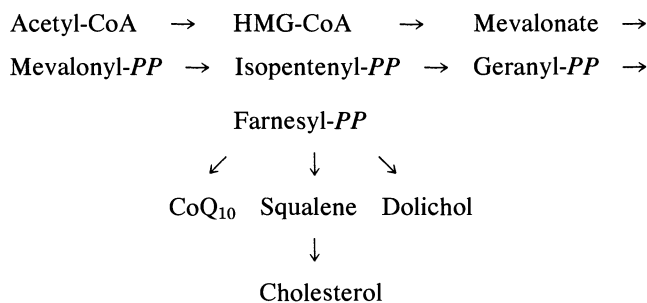


FIG. 1. Biosynthesis of cholesterol and coenzyme Q (CoQ) from acetyl-CoA. HMG-CoA, 3-hydroxy-3-methylglutaryl-coenzyme A; PP, pyrophosphate.

CoA reductase than ML-236 B. This metabolite became known as lovastatin (Mevacor), having structure I (Fig. 2).

Side effects of lovastatin have been summarized (6). Generally, it is well tolerated. Reported adverse experiences have been mild. About 2% of patients were discontinued in both controlled and uncontrolled studies due to side effects that were of the gastrointestinal tract, musculoskeletal system, nervous system/psychiatric, and skin. Additionally, liver dysfunction from lovastatin does occur and 0.5% of patients develop a myopathy. Eye dysfunctions, indicated by a high prevalence of baseline lenticular opacities, have been reported. In clinical trials, the appearance of new opacities was noted. The causal relationship of lovastatin to these opacities was not established. Of 431 patients, 34 had opacities at the final examination, which occurred 5–15 months after initiation of lovastatin therapy.

The inhibition of HMG-CoA reductase to reduce tissue levels of cholesterol in the human by limiting the intrinsic biosynthesis of cholesterol would be seen to inhibit also the intrinsic biosynthesis of CoQ<sub>10</sub>. However, it was reported (6) that "Because Mevacor does not inhibit HMG-CoA reductase completely, biologically necessary amounts of mevalonate are available." This statement implies that tissue levels of CoQ<sub>10</sub> (II, Fig. 2) in the human body are not reduced to an extent that would be of clinical detriment to a patient.

The overwhelming international evidence over at least 15 years on the indispensability of CoQ<sub>10</sub> for human cardiac function (e.g., see refs. 7–12) necessitated the determination of whether lovastatin limits the intrinsic biosynthesis of CoQ<sub>10</sub> as it limits cholesterol. Three related protocols were pursued for this determination. One protocol was based on the administration of lovastatin to rats and is reported in the preceding paper (13). The second protocol was based on the administration of lovastatin to typical cardiac patients in mild (class I) to severe (class IV) stages of cardiomyopathy. This protocol was conducted in a clinical practice in which lov-

The publication costs of this article were defrayed in part by page charge payment. This article must therefore be hereby marked "advertisement" in accordance with 18 U.S.C. §1734 solely to indicate this fact.

Abbreviations: HMG-CoA, 3-hydroxy-3-methylglutaryl-coenzyme A; CoQ, coenzyme Q.

<sup>†</sup>To whom reprint requests should be addressed.

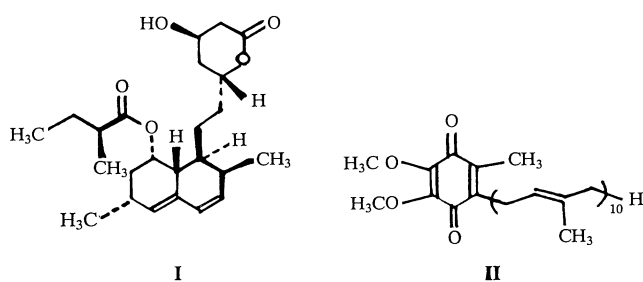


FIG. 2. Structures of lovastatin (I) and CoQ<sub>10</sub> (II).

astatin was administered to such patients for reduction of levels of cholesterol to minimize this risk of cardiac disease. Since biochemical data for typical patients in a hospital setting are necessarily limited, a third protocol was conducted with a volunteer who allowed extraordinary monitoring of levels of CoQ<sub>10</sub>, cholesterol, and cardiac function to permit high statistical significance, which is not readily feasible in monitoring patients in a hospital.

#### Protocol I. Treatment of Rats with Lovastatin

The treatment of groups of rats with lovastatin and CoQ<sub>10</sub> is separately detailed (13). Group I consisted of control animals on a standard diet. Group II consisted of rats treated with lovastatin. Group III consisted of rats treated with lovastatin and CoQ<sub>10</sub>. The lovastatin was purchased from a pharmacy to be identical with that prescribed for patients. CoQ<sub>9</sub> (intrinsic to the rat) levels were decreased significantly ( $P < 0.01$ ) in blood and liver of lovastatin-treated rats, as were the CoQ<sub>10</sub> levels in heart tissue. In the group treated with lovastatin and CoQ<sub>10</sub>, levels of CoQ<sub>10</sub> in blood were increased ( $P < 0.01$ ). Decreases in CoQ<sub>9</sub> in the heart and liver were also diminished in the CoQ<sub>10</sub>-treated group.

In summary, treatment of the rats with lovastatin decreased the levels of CoQ<sub>9</sub> in the blood, heart, and liver, and supplementation with CoQ<sub>10</sub> increased the CoQ<sub>10</sub> levels in these tissues to or above control levels.

#### Protocol II. Cardiac Patients Treated with Lovastatin

**Patient H.V.** This patient, a 55-year-old White man with ischemic cardiomyopathy, class III (minimal activity causes distress; New York Heart Association), was treated with 100 mg of CoQ<sub>10</sub> daily in May 1984. The control blood level of CoQ<sub>10</sub> was 0.67  $\mu\text{g}/\text{ml}$ ; the control ejection fraction (percent of volume of blood ejected per beat) was 60%. One month later (June 1984), the CoQ<sub>10</sub> level had increased to 1.73  $\mu\text{g}/\text{ml}$  and the ejection fraction had increased to 74%. From July 1984 to September 1987, administration of CoQ<sub>10</sub> maintained a therapeutic level of CoQ<sub>10</sub> of 1.73–2.78  $\mu\text{g}/\text{ml}$  and an ejection fraction of 64–70%. During these 3 years of therapy with CoQ<sub>10</sub>, the ischemic cardiomyopathy decreased from class III to class II (ordinary activity causes symptoms) and the quality of life significantly improved. Beginning in September 1987, H.V. was treated with 40 mg of lovastatin daily and by March 1988 the patient had steadily deteriorated from a livable class II to near class IV, known to be life-threatening. In this deterioration, the patient exhibited clinical decompensation and chest pain and required surgical revision of one graft. His blood CoQ<sub>10</sub> level was 2.52  $\mu\text{g}/\text{ml}$  in September 1987 when treatment with lovastatin was initiated. About 6 months later (March 1988) his blood CoQ<sub>10</sub> level had diminished to 1.15  $\mu\text{g}/\text{ml}$ , and by August 1988 it had decreased to the very low level of 0.64  $\mu\text{g}/\text{ml}$  and the ejection fraction had diminished to 54%. During the surgical period, it was not feasible to administer CoQ<sub>10</sub> for 3 weeks, but administration of CoQ<sub>10</sub> was resumed at 166 mg/day in

August 1988. The blood CoQ<sub>10</sub> increased to 1.39  $\mu\text{g}/\text{ml}$  in one month and was stabilized at 1.55  $\mu\text{g}/\text{ml}$  in November 1988 and 1.66  $\mu\text{g}/\text{ml}$  in April 1989. The administration of lovastatin was reduced from 40 mg/day to 20 mg/day in November 1988. The depressed CoQ<sub>10</sub> levels from lovastatin, which in conjunction with the reduction of the dosage of lovastatin and an increase in the dosage of CoQ<sub>10</sub> to 166 mg allowed cardiac stabilization with acceptable blood levels of CoQ<sub>10</sub> and ejection fractions.

Clearly, the administration of lovastatin to H.V. over time significantly reduced blood levels of CoQ<sub>10</sub> and reduced the pumping of blood by the heart as monitored by the determination of the ejection fraction.

**Patient B.C.** This patient was a 46-year-old White man with dilated cardiomyopathy (class III); the control blood level of CoQ<sub>10</sub> was 0.78  $\mu\text{g}/\text{ml}$ ; the control ejection fraction was 62% in October 1984. His blood CoQ<sub>10</sub> increased 1.79–2.31  $\mu\text{g}/\text{ml}$  and his ejection fraction increased to 68–71% while he received 100 mg of CoQ<sub>10</sub> per day. During this 24-month period, his cardiac function and his quality of life improved from class III to class I (ordinary activity causes no discomfort) and his cardiac function stabilized at a clinically reasonable level.

Beginning in April 1987 he was given 20 mg of lovastatin daily; 6–18 months later, his blood CoQ<sub>10</sub> levels steadily declined from 2.29 to 1.82 to 1.50 to 1.12  $\mu\text{g}/\text{ml}$ . In October 1988 the administration of lovastatin was terminated and by March 1989 his blood CoQ<sub>10</sub> level had increased to 1.87  $\mu\text{g}/\text{ml}$ . Cardiac status changed from class II to class I. Blood levels of CoQ<sub>10</sub> decreased over time from the administration of lovastatin. Blood levels of CoQ<sub>10</sub> increased when the administration of lovastatin was terminated.

**Patient S.F.** S.F., a White woman of age 43 years (now 46), had dilated cardiomyopathy in severe class IV when treatment with CoQ<sub>10</sub> (100 mg per day) was initiated. Between March 1986 and September 1987, her blood CoQ<sub>10</sub> levels ranged from 1.68 to 4.5  $\mu\text{g}/\text{ml}$  and her ejection fraction ranged from 52% to 60%. Her clinical status improved to class III.

Treatment with 20 mg of lovastatin was initiated in September 1987, and by March 1988 her CoQ<sub>10</sub> levels had dropped to 2.5  $\mu\text{g}/\text{ml}$ , her cardiac condition had significantly deteriorated to a severe class IV, and she was referred for a heart transplant.

In March 1988 her dosage of CoQ<sub>10</sub> was increased to 200 mg daily and blood levels of CoQ<sub>10</sub> increased to 4.24–5.43  $\mu\text{g}/\text{ml}$  between October 1988 and April 1989. At the end of that period, her cardiac condition had significantly improved from class IV to class III, which we attribute to the increase in daily dosage of CoQ<sub>10</sub> to 200 mg in the presence of continuing daily treatment with 20 mg of lovastatin.

This patient was initially in class IV and her cardiac status improved to class III after treatment with CoQ<sub>10</sub>. After treatment with lovastatin was added, she deteriorated from class III to severe class IV so rapidly that she was referred for a cardiac transplant. After her dosage of CoQ<sub>10</sub> was increased from 100 to 200 mg daily, the ejection fraction improved and she was reclassified to class III.

**Patient M.O.** M.O. was a 72-year-old White woman in class III with dilated cardiomyopathy. In March 1986 her blood level of CoQ<sub>10</sub> was 0.79  $\mu\text{g}/\text{ml}$  and her ejection fraction was 58%. On supplementation with 100 mg of CoQ<sub>10</sub> daily, her CoQ<sub>10</sub> blood level, after 3 months, was 1.21  $\mu\text{g}/\text{ml}$  but the ejection fraction remained at 58%. In September 1986 the CoQ<sub>10</sub> dosage was increased to 133 mg daily and during March to September 1987 her blood CoQ<sub>10</sub> levels were 1.70 and 2.23  $\mu\text{g}/\text{ml}$  with an improved ejection fraction of 62–64%.

In September 1987 the administration of lovastatin was initiated at 20 mg daily. By March 1988 the blood CoQ<sub>10</sub> level

Table 1. CoQ<sub>10</sub> and cholesterol levels and cardiac function

	Initial (day 0)	Lovastatin (day 29)	Lovastatin plus CoQ <sub>10</sub> (day 35)	CoQ <sub>10</sub> (day 40)
Blood CoQ <sub>10</sub> , $\mu\text{g/ml}$	1.38	1.12	1.42	2.22
Stroke volume, ml	63.3	49.3	59.7	89.9
Cardiac output, $\text{min}^{-1}$	4.5	3.7	4.2	6.0
Cardiac index	1.85	1.60	1.82	2.58
Heather index*	10.89	8.50	8.70	11.4
Cholesterol, mg/dl	233.7	194.3	160.7	217.0

\*Index of contractility.

had decreased to 0.99  $\mu\text{g/ml}$  and the ejection fraction was 61%. In August 1988 her blood level of CoQ<sub>10</sub> was 1.68  $\mu\text{g/ml}$  and in February 1989 it was 1.00  $\mu\text{g/ml}$ . With a further increase of CoQ<sub>10</sub> dosage to 166 mg daily, her blood level increased to 3.0  $\mu\text{g/ml}$  and her ejection fraction ranged from 76–67%. When this 72-year-old female with class III cardiomyopathy was treated with CoQ<sub>10</sub>, her cardiomyopathy improved to class II in 12 months. On administration of lovastatin her blood CoQ<sub>10</sub> level significantly diminished, and with deterioration in clinical status, but not in the ejection fraction.

**Patient J.G.** This patient, a 66-year-old White man with ischemic cardiomyopathy, was in class I when lovastatin, 20 mg daily, was initiated in January 1988. The ejection fraction was 85%. One year later, the CoQ<sub>10</sub> level was 0.61  $\mu\text{g/ml}$  and the ejection fraction had decreased to 52%. Treatment with CoQ<sub>10</sub>, 100 mg daily, was initiated at that time because the cardiomyopathy had definitely worsened to class III. By March 1989 the CoQ<sub>10</sub> level was 1.02  $\mu\text{g/ml}$  and the ejection fraction was 61%. The dosage of CoQ<sub>10</sub> was increased to 133 mg daily, and within 3 months the ejection fraction had increased to 66%.

### Protocol III. Study of Volunteer with Hypercholesterolemia

A 43-year-old White man who was eligible for treatment with lovastatin volunteered to take lovastatin and allow an extraordinary number of measurements of blood levels of CoQ<sub>10</sub> ( $n = 30$ ) and cholesterol ( $n = 30$ ) and measurements of cardiac function by noninvasive impedance cardiography ( $n = 18$ ). Blood samples and measurements of cardiac function were taken on three successive days prior to initiation of treatment with lovastatin at 40 mg/day. On day 29, the volunteer was treated with 200 mg of CoQ<sub>10</sub> per day in addition to the lovastatin. On day 35, treatment with lovastatin terminated. The supplementation with CoQ<sub>10</sub> was continued to the end of the protocol at day 40. Blood samples were collected and measurements of cardiac function were taken repeatedly throughout the 40-day period (Table 1).

The treatment with lovastatin resulted in a marked decrease in plasma cholesterol. Levels of CoQ<sub>10</sub> also decreased, and this was accompanied by a measurable decrease in cardiac function. Supplementation with CoQ<sub>10</sub> caused the blood CoQ<sub>10</sub> levels to increase to pre-lovastatin levels and was accompanied by improved cardiac function.

## DISCUSSION

Lovastatin is a very successful drug in the treatment of patients with hypercholesterolemia. It lowers tissue levels of cholesterol and, thereby, reduces one's risk of cardiac disease. Lovastatin inhibits HMG-CoA reductase, the enzyme that catalyzes the second step in the pathway from acetyl-CoA to cholesterol. This multireaction pathway also yields CoQ<sub>10</sub> (Fig. 1). Inadequate knowledge has been available on whether lovastatin decreases the biosynthesis of CoQ<sub>10</sub> as it does the biosynthesis of cholesterol. The primary report has been that lovastatin "does not inhibit HMG-CoA reductase

completely, necessary amounts of mevalonate are available," which implies that available mevalonate yields necessary amounts of CoQ<sub>10</sub>.

Since lovastatin reduces the intrinsic biosynthesis of cholesterol, which in turn reduces a risk factor of cardiac disease and, since CoQ<sub>10</sub> is established to be indispensable to cardiac function, it became imperative to determine whether or not lovastatin reduces levels of CoQ<sub>10</sub> in humans, particularly in cardiac patients who are likely to be placed on lovastatin therapy. Over 1.4 million patients in the United States (57% of the market) have been treated with Mevacor, and this drug is sold in over 30 countries (14).

Three related protocols were pursued. In protocol I, rats were treated with lovastatin or with lovastatin plus CoQ<sub>10</sub>, and concentrations of CoQ were measured in blood, heart, and liver samples. Protocol II consisted of monitoring patients in a hospital who were being treated with lovastatin in the commonly practiced manner. Protocol III consisted of extraordinary monitoring of CoQ<sub>10</sub> and cholesterol levels and cardiac function in a volunteer eligible for lovastatin treatment because of hypercholesterolemia. The results of all three protocols reinforced the results of the individual protocols and demonstrated that administration of lovastatin does indeed lower tissue levels of CoQ<sub>10</sub>, which may decrease cardiac function to variable degrees. Therefore, lovastatin may not totally inhibit HMG-CoA reductase, but it does inhibit this enzyme sufficiently to depress biosynthesis of both CoQ<sub>10</sub> and cholesterol.

These findings have important implications for the use of lovastatin (or other drugs that inhibit HMG-CoA reductase) in the treatment of hypercholesterolemia. People who have high tissue levels of CoQ<sub>10</sub> and strong cardiac functions may be able to withstand having their CoQ<sub>10</sub> levels depressed by lovastatin without overt adverse effects, but people who have low tissue levels of CoQ<sub>10</sub> and a modest or poor cardiac function and are treated with lovastatin may be subjected to a possible increased impairment of health and even to a life-threatening status. Young people as well as old can have low body levels of CoQ<sub>10</sub> and low cardiac function.

The New York Heart Association has classified cardiac disease in four categories: class I, ordinary activity causes no discomfort; class II, ordinary activity causes symptoms; class III, minimal activity causes distress; and class IV, the patient is symptomatic at rest. Our protocol II involved patients who were 43, 46, 55, 66, and 72 years old, all of whom were diagnosed by a cardiologist as having some degree of cardiac disease, but who were nevertheless treated with lovastatin. The youngest, 43 years, was in class IV because of being symptomatic at rest but was improved to class III and then deteriorated to a severe class IV on treatment with lovastatin and was eligible for a cardiac transplant. The 46-year-old patient in class III improved to class I on treatment with CoQ<sub>10</sub> and clinically deteriorated with a decrease in CoQ<sub>10</sub> levels on treatment with lovastatin. The 55-year-old patient in class III improved to class II on treatment with CoQ<sub>10</sub> and then alarmingly deteriorated to class IV on treatment with lovastatin. The 66-year-old patient in class I deteriorated to class III on lovastatin but clinically improved

on treatment with CoQ<sub>10</sub>. The 72-year-old patient in class III improved to class II on treatment with CoQ<sub>10</sub> and had a significantly decreased CoQ<sub>10</sub> blood level after lovastatin treatment, with definite clinical deterioration.

In these five cases, ejection fractions were calculated from analyses of systolic time intervals, a method that generally yields values about 15 absolute percentage points higher than those obtained by other methods.

Clearly, before prescribing lovastatin for hypercholesterolemia in patients >40 years old, physicians should take into account the presence of any degree of cardiac disease from class I to class IV if increased cardiac distress is to be avoided. On the basis of our data showing the reduction of tissue levels of CoQ<sub>10</sub> and impaired cardiac function from administration of lovastatin to patients with hypercholesterolemia, we suggest that such patients should be treated with both CoQ<sub>10</sub> and lovastatin.

It is anticipated that some of the side effects from lovastatin, particularly liver disease, may be caused by the depression of body levels of CoQ<sub>10</sub> by lovastatin. Although the side effects of liver disease and opacities in the eyes may occur in only a low percentage of patients treated, such side effects may be of paramount significance to the individuals so afflicted.

Although our study focused on cardiac function, the knowledge of the essentiality of CoQ<sub>10</sub> to bioenergetics is the basis for protecting all patients having hypercholesterolemia from a reduction in bioenergetics which sustains all life functions.

**Note.** By personal communication, Gian Paolo Littarru has informed K.F. that he and Silvio Lippa and their medical associates at Catholic University in Rome have recently recorded a reduction in blood levels of CoQ<sub>10</sub> when patients were treated with lovastatin for hypercholesterolemia.

Appreciation is expressed to the Robert A. Welch Foundation of Houston, for support of this research.

1. Friedman, G. D., Kannel, W. B., Dawber, T. R. & McNamara, P. M. (1966) *Am. J. Epidemiol.* **83**, 366–378.
2. Shaper, A. G., Pocock, S. J., Walker, M., Phillips, A. N., Whitehead, T. P. & Macfarlane, P. W. (1985) *J. Epidemiol. Community Health* **39**, 197–209.
3. Endo, A., Kuroda, M. & Tsujita, Y. (1976) *J. Antibiot.* **29**, 1346–1348.
4. Brown, A. G., Smale, T. C., King, T. J., Hasenkamp, R. & Thompson, R. H. (1976) *J. Chem. Soc. Perkin Trans. 1*, 1165–1170.
5. Alberts, A. W., Chen, J., Kurin, G., Hunt, V., Huff, J., Hoffman, C., Rothrock, J., Lopez, M., Joshua, H., Harris, E., Patchett, A., Monaghan, R., Currie, S., Stapley, E., Albers-Schonberg, G., Hensens, O., Hirshfield, J., Hoogsteen, K., Liesch, J. & Springer, J. (1980) *Proc. Natl. Acad. Sci. USA* **77**, 3957–3961.
6. Merck Sharp & Dohme (1988) *Product Monogr.* **11**, L5920-10, 1288.3561.
7. Folkers, K., Wantabe, T. & Kaji, M. (1977) *J. Mol. Med.* **2**, 431–460.
8. Langsjoen, P. H., Folkers, K., Lyson, K., Muratsu, K., Lyson, T. & Langsjoen, P. (1988) *Klin. Wochenschr.* **66**, 583–590.
9. Langsjoen, P. H., Langsjoen, P. & Folkers, K. (1990) *Am. J. Cardiol.* **65**, 521–523.
10. Oda, T. (1986) in *Biomedical and Clinical Aspects of Coenzyme Q<sub>10</sub>*, eds. Folkers, K. & Yamamura, Y. (Elsevier Science, New York), Vol. 5, pp. 269–281.
11. Mortensen, S. A., Bouchelouche, P., Muratsu, K. & Folkers, K. (1986) in *Biomedical and Clinical Aspects of Coenzyme Q<sub>10</sub>*, eds. Folkers, K. & Yamamura, Y. (Elsevier Science, New York), Vol. 5, pp. 281–290.
12. Judy, W. V., Hall, J. H., Toth, P. D. & Folkers, K. (1986) in *Biomedical and Clinical Aspects of Coenzyme Q<sub>10</sub>*, eds. Folkers, K. & Yamamura, Y. (Elsevier Science, New York), Vol. 5, pp. 291–302.
13. Willis, R. A., Folkers, K., Tucker, J. L., Ye, C.-Q., Xia, L.-J. & Tamagawa, H. (1990) *Proc. Natl. Acad. Sci. USA* **87**, 8928–8930.
14. Merck and Co., Inc. (1990) *First Quarter Report*.